

Total knee replacement modifies the preoperative tibial torsion angle—similar results between computer-assisted and standard technique

Daniel Hernandez-Vaquero^{1,2}, Alfonso Noriega-Fernandez², Sergio Roncero-Gonzalez², Andres A. Sierra-Pereira², Manuel A. Sandoval-Garcia²

¹School of Medicine, University of Oviedo, Oviedo, Asturias, Spain; ²Department of Orthopaedic Surgery, Hospital St Agustin, Aviles, Spain

Contributions: (I) Conception and design: D Hernandez-Vaquero; (II) Administrative support: D Hernandez-Vaquero, A Noriega-Fernandez; (III) Provision of study materials or patients: D Hernandez-Vaquero, A Noriega-Fernandez, S Roncero-Gonzalez; (IV) Collection and assembly of data: S Roncero-Gonzalez, AA Sierra-Pereira, MA Sandoval-Garcia; (V) Data analysis and interpretation: MA Sandoval-Garcia; (VI) Manuscript writing: All authors; (VII) Final approval of manuscript: All authors.

Correspondence to: Daniel Hernandez-Vaquero. Department of Orthopaedic Surgery, Hospital Universitario San Agustin, Heros, 4, 33405 Aviles, Asturias, Spain. Email: danielhvaquero@gmail.com.

Background: Malpositioning of the components in total knee replacement (TKR) can result in failure or deficient outcomes of the surgical procedure. In the tibial segment, the rotational position of the tray should reproduce the mechanical axis without modifying physiological tibial torsion.

Methods: A randomised, prospective study was made of 74 patients subjected TKR involving the standard technique (38 cases) and navigation surgery (36 cases). A computed tomography study of the knee and ankle was made before the operation and after arthroplasty implantation, in order to identify the position of the prosthetic tibial tray in the transverse axis and the tibial torsion angle.

Results: The rotation of the tibial tray changed from its preoperative to postoperative range, but no significant differences were found between the navigated and the standard groups. The presence of preoperative deformities in the frontal plane did not modify the changes in the rotation of the tibial component. The mean preoperative tibial torsion angle was 17.76° (SD =10.15) of external rotation, with no significant differences in relation to the previous frontal deformity. After TKR, the tibial torsion angle was 15.36° (SD =7.16) (P=0.021). There were no differences in final tibial torsion between the knees operated upon with the standard instruments and those subjected to computer-assisted surgery (CAS; P=0.157).

Conclusions: TKR surgery modifies preoperative tibial torsion. Neither mechanical instrumentation nor navigation surgery precisely reproduces the rotational axis of the leg.

Keywords: Computer-assisted; tibial component; tibial torsion; total knee replacement (TKR)

Submitted Jan 17, 2018. Accepted for publication Feb 04, 2018.

doi: 10.21037/atm.2018.02.15

View this article at: <http://dx.doi.org/10.21037/atm.2018.02.15>

Introduction

Despite the good clinical outcomes of total knee replacement (TKR), a significant percentage of patients are not satisfied with the procedure, and a 6% and 12% failure rate after 5 and 10 years, respectively, can be expected (1). Although the cause of failure often cannot be identified, the

literature emphasises the need for correct positioning of the tibial and femoral components (2,3)—this appearing to be crucial in order to obtain good long-term outcomes.

Intra- or extramedullary guides can be used to achieve good alignment in the tibial axis. Both techniques use visible or palpable anatomical references in the proximal portion of

the tibia, in the ankle or in the foot, and this introduces subjectiveness. Different references have been considered in the proximal tibia (4-9), and varus cuts have been shown to be the most frequent error when implanting this component (10-13). Neither technique is completely satisfactory and defective alignment has been reported in 2-40% of the cases (14-16).

In the cross-sectional plane, correct orientation of the tibial plate is only possible if performed according to the mechanical axis, and this requires knowing the axis of the entire tibia. It is not enough to adequately position the tray according to the upper zone of the tibia: positioning must be made according to the full axis of the bone. The introduction of computer-assisted surgery (CAS) has improved TKR positioning in the frontal axis, avoiding outliers, and has demonstrated its usefulness particularly in major varus-valgus deformities (17,18). However, it has not been demonstrated that CAS improves tibial tray placement in the transverse axis (19).

The proximal tibial epiphysis is internally rotated with respect to the distal one. Few studies have analysed the position of the tibial tray in relation to the rotational axis of the tibia and physiological tibial torsion. The effects of tibial torsion upon TKR alignment and the changes in torsion that may occur after arthroplasty implantation have not been investigated. Placement of the tibial tray may possibly modify such torsion permanently, with the consequences this may have for the clinical outcome of the procedure. On the other hand, it should be determined whether the technique used for TKR (mechanical instrumentation or navigation surgery) modifies the position of the tibial tray and precisely reproduces the rotation desired by the surgeon.

The objectives of the present study are to:

- ❖ Determine preoperative tibial torsion found from the angle between the axis of the tibial plateau and the axis of the ankle;
- ❖ Determine whether tibial torsion is modified in cases of frontal varus-valgus deformity;
- ❖ Determine postoperative tibial torsion following TKR surgery;
- ❖ Compare tibial torsion before and after implantation of the tibial tray;
- ❖ Compare postoperative tibial torsion following TKR with the standard technique and with CAS.

Although the present study exclusively focuses on radiological alignment, it is assumed that alterations in the rotational axis of the tibia will have an impact upon the clinical outcome and the survival of TKR.

Methods

Seventy-four patients (48 women and 26 men) were enrolled in a randomised prospective study to analyse via CT the position of the prosthetic tibial tray and tibial torsion before and after TKR implant. In one group, TKRs were implanted with standard equipment; in another group CAS was used. Patients were randomly assigned to each group by means of a random number table. The study methodology of our cases has already been published in a previous paper (19). The angulation obtained was taken to be the mean of the values recorded by the two observers. In all cases, the original diagnosis was tricompartmental arthrosis and the procedures were carried out by surgeons with ample experience in TKRs, both computer assisted and standard surgery. Institutional review board approval was obtained and informed consent was obtained from all individual participants included prior to participating in this study.

The mean age of patients was 61.3 years (SD =7.03); mean body mass index (BMI) was 28.94 (SD =5.24; range, 20.68-42.60) kg/m². The implant model used in all cases was the Triathlon arthroplasty (Stryker, Kalamazoo, MI, USA). A wireless image-free navigation system was used (Stryker Image Free Computer Navigation System, Stryker-Leibinger, Freiburg, Germany) in CAS group. In the tibia, the points and areas referenced in the navigation system were the centre of the superior tibial plateau, the tibial plateau surface, tibial plateau axis, internal malleolus, external malleolus and axis of the ankle. In the standard group an extramedullary guide was employed for tibial implant, taking the patellar tendon insertion (middle 1/3 of the tubercle), the midpoint of the ankle and the axis of the second toe as references.

All patients received a radiography of the lower extremity during the preoperative assessment, which was repeated a month after TKR implantation. The mechanical axis of the limb and the angulation of the femoral and tibial components were measured on the radiographies with the Impax 6.3.1.2813 system (Agfa Healthcare NV, Mortsel, Belgium) and the Agfa-Orthopaedic Tools software version 2.06. Varus deformities were considered as negative angulation and valgus as positive.

A CT was performed in all patients of the proximal tibia and ankle, both preoperatively and after surgery. The tomograph used was a Siemens AG Somatron-Volume Access, version A40A (Siemens A.G. Munich, Germany). On average, four cuts were performed, and the point closest to the articular surface was chosen. A line was traced

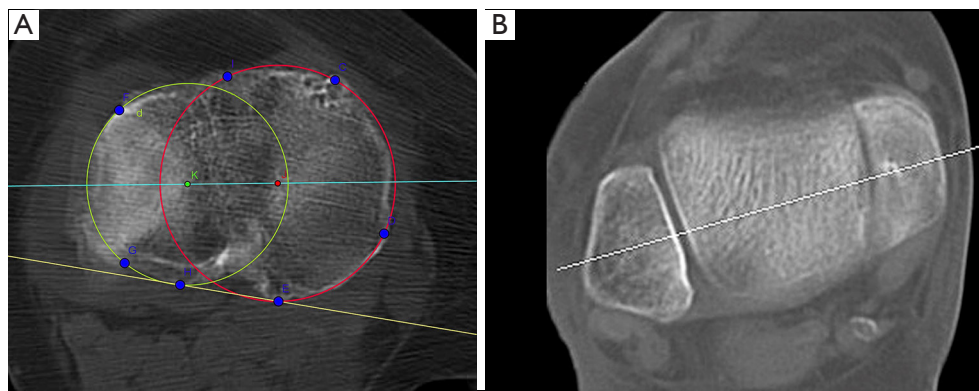


Figure 1 Tibial proximal angle (line which connected the geometric centers of the plateaus and line tangent to the posterior tibial outline) and identification of the axis of the ankle.

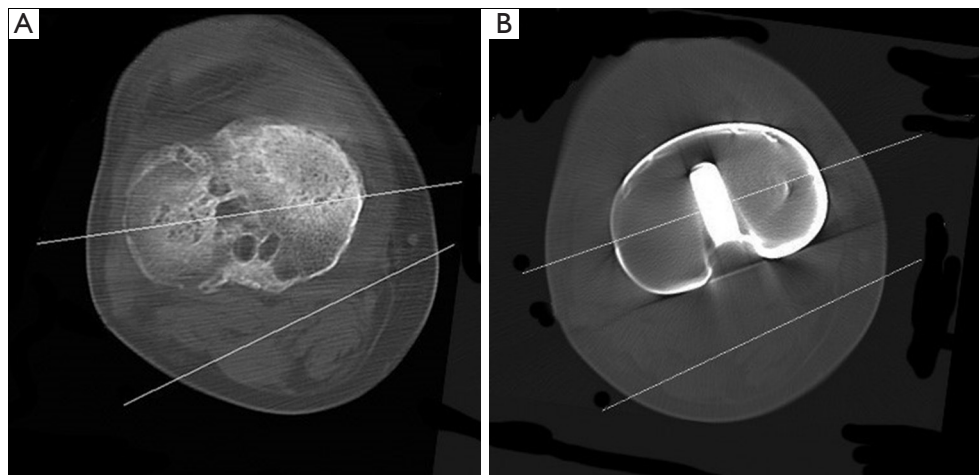


Figure 2 Tibial torsion angle. Superimposition of the line joining the geometric centres of the tibial plateau and axis of the ankle. Preoperative and postoperative situation.

which connected the geometric centers of the plateaus, and parallel to the patellar tendon shadow. The angle between this line and the tangent to the posterior tibial outline was found (*Figure 1*). In the ankle, cuts were performed with the same thickness and separation at the tibial-fibular-talar articular interline. A line parallel to the talus axis was traced which passed through the three aforementioned bones (*Figure 2*). The angle formed by the line connecting the geometric centers of the plateaus and the axis of the ankle was labeled tibial torsion angle.

After surgery, the tibial torsion angle was determined relative to the line between the geometric centers of the two circumferences which composed the outer rim of the prosthetic tray and the axis of the ankle, previously

described (*Figure 3*). External rotation was considered as positive angle and internal as negative.

Statistical analysis

A descriptive study was performed to obtain means and standard deviations for all quantitative variables. The relations between angle measurements were analyzed via Pearson's correlation and the intraclass correlation coefficient. Chi-square and ANOVA were carried out to compare preoperative differences between groups of qualitative and quantitative variables, respectively. Paired student's t-test was performed to assess changes in the quantitative variables between the preoperative

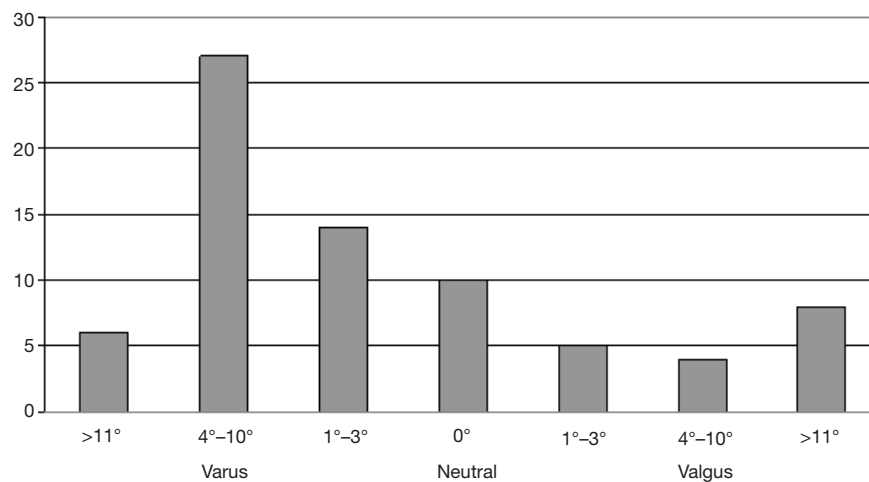


Figure 3 Preoperative varus, valgus and neutral alignment.

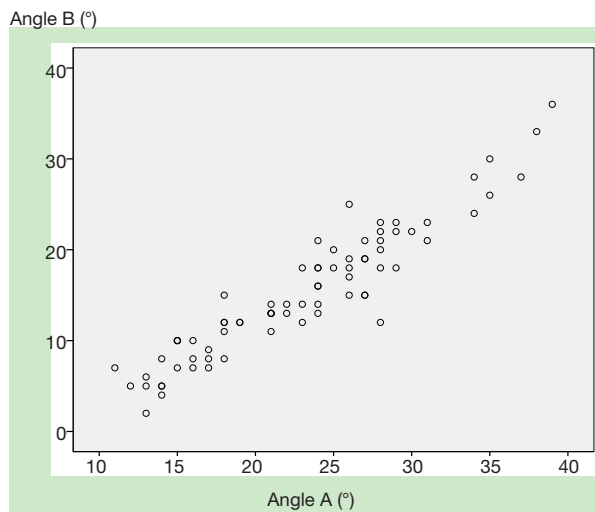

Figure 4 Correlation between the two preoperative measurements of the tibia (A, posterior tangent; B, plateau centre) and the axis of the ankle.

and postoperative scenarios (paired samples). A repeated measures ANOVA (General Linear Model) was used to compare the evolution of angular variables preoperatively and postoperatively between the standard and navigated groups taking the time of measurement as an intra-subject factor and the study group as inter-subject factor. Statistical signification was considered when $P < 0.05$.

Results

Thirty-six TKRs were performed with CAS, and 38

with standard technique. Both groups were similar in terms of age, BMI, gender and preoperative deformity. The rotation of the tibial component changed by 5.28° (mean) from its preoperative to postoperative range, but no significant differences were found between the navigated and the standard groups. The presence of preoperative deformities in the frontal plane (greater or lesser than 4°) did not modify the changes in the rotation of the tibial component. In the general series, the mean preoperative tibial torsion angle was 23.04° (SD =6.78) on considering the tangent posterior to the tibial plateau and the axis of the ankle (Angle A), and 17.76° (SD =10.15) on considering the line joining the centres of the tibial plateaus and the axis of the ankle (Angle B). Both angles were closely correlated ($P < 0.01$; Pearson's r : 0.97) (Figure 4).

On taking preoperative frontal varus-valgus deformity as variable, tibial torsion was seen to decrease 2.37° in varus knees $\geq 4^\circ$ (33 cases), 1.94° in neutral frontal axis knees (29 cases), and 1° in valgus knees $\geq 4^\circ$ (12 cases). These differences were not significant ($P = 0.884$) (Table 1).

In the postoperative period, the angle between the axis of the ankle and the line joining the centre of the platforms of the prosthetic tibial tray was 15.66° (SD =7.40). The difference between preoperative tibial torsion, taking as reference the line joining the centre of the tibial plateaus (Angle B: 17.76° on average), and postoperative torsion was statistically significant ($P = 0.021$). There were no differences in postoperative tibial torsion between the knees operated upon with the standard instruments and those subjected to CAS ($P = 0.157$) (Table 2).

Table 1 Modification of tibial torsion (angle B) according to the preoperative frontal axis. Mean (°)

Preoperative limb axis	Preoperative angle B (SD)	Postoperative angle B with CAS	Postoperative angle B with ST	Postoperative angle B (SD)
Varus	16.00 (8.56)	12.53	14.11	13.63 (6.01)
Normal	18.57 (12.35)	15.52	17.68	16.83 (8.67)
Valgus	19.30 (8.45)	17.02	20.19	18.30 (6.75)
Total	17.76 (10.15)	13.97	17.38	15.66 (7.41)

CAS, computer-assisted surgery.

Table 2 Torsion and rotation data (mean) pre and postoperative using ST or CAS

Measurement	Preoperative	Postoperative (ST)	Postoperative (CAS)
Tibial torsion	17.76°	17.38°	13.97°
Tibial plate rotation	23.20°	18.45°	17.21°

CAS, computer-assisted surgery.

Discussion

The present study shows that while CAS improves the frontal axis in TKR, this technique does not modify the rotational position of the tibial tray when compared with that obtained on using the standard procedure. In turn, we have found that measurement of the rotational axis of the tibia can be made indistinctly through the tangent posterior to the plateau (which we have called A) or with the line joining the centre of the tibial plateaus (called B), since there is close correlation between both measurements. On the other hand, we have seen that tibial torsion changes after TKR, with no significant differences according to the prior deformity of the frontal axis or the use of CAS.

Studies demonstrate a range of tibial component malpositioning exceeding 30° (20), and it is considered that positioning of the tibial tray in internal rotation is a frequent error seen in almost 5% of all TKR procedures. Such malpositioning in the transverse axis is a known cause of implant failure. Nicoll and Rowley (21) have found the mean rotation of the tibial component to be 4.3° of internal rotation in the painful group and 2.2° of external rotation in the pain-free group. Positioning the tibial tray in slight external rotation appears to be associated to better outcomes on the clinical scales (2,22,23). There is no consensus in the literature regarding the ideal rotation of this component in TKR implantation, and agreement is likewise lacking regarding the best way to orientate its placement during surgery (17).

Many techniques have been proposed to achieve improved positioning of the tibial component in the rotational plane (24–26). Reported references have been the medial border of the tibial tuberosity, the medial third of the tibial tuberosity, the anterior tibial crest, the posterior tibial condylar line, the second ray and the first web space of the foot. The disadvantage of all anatomical landmark techniques is that they do not account for femoro-tibial kinematics; consequently, the range of motion (ROM) technique with the implanted test components is the most widely recommended approach (22). However, as an isolated method, such self-alignment tends to position the component more internally when the described anatomical references are considered (17). In any case, no system offers uniform results, and this is important, since an error of 1 mm in palpating the tibial tubercle is known to imply a rotational deviation of 5°.

The use of CAS has not represented an advantage in tibial tray placement in the transverse axis. On taking references in the malleoli and in the axis of the ankle, it was believed that that the position of this component could be improved. CAS can improve tibial component alignment and minimise the outliers in frontal lower limb alignment after TKR surgery (27,28), but there is no agreement in the literature regarding the usefulness of this technique in terms of the rotational position of the components (29).

Physiological tibial torsion results in external rotation of

the distal portion in relation to the proximal segment. Tibial torsion is difficult to measure through clinical exploration and standard X-rays (30). Measuring tibial rotation with CT is more complex than femur and does not comply with uniform rules. Alignment with respect to the tibial plateaus seems more exact than the anterior or posterior borders of the tibia or the position of the anterior tuberosity, which may be altered due to arthritic changes. The axis of the ankle was found choosing the CT cut in which both malleoli and the talus were visible. In our series, a great correlation was found between the proximal rotational angle measured with the posterior tangent to the tibial plateau and the angle measured with the posterior rim. This finding implies it would not be necessary to gather information about the posterior rim of the plateau, a process which can actually lead to errors due to how difficult it is to accurately visualize that line. The rotation of the prosthetic components was estimated following the same anatomical landmarks as in the preoperative assessment, but added the position of the implant.

According to the classical studies, it can be considered that mean tibial torsion in the adult is close to 20° external rotation (31). However, tibial torsion showed a wide range of variation in the series analyzed. In the literature the range of external rotation varies between 50° and 15° (8,13,16,32,33) depending on patient race, personal characteristics, the anatomical reference used in the proximal zone and ankle, or the radiological technique used. These results may further explain the higher rate of outliers found on studying the rotation of the components in TKR (16). In our study the mean preoperative tibial torsion angle was 23.04° (SD =6.78) on considering the tangent posterior to the tibial plateau and the axis of the ankle, and 17.76° (SD =10.15) on considering the line joining the centres of the tibial plateaus and the axis of the ankle. These figures are consistent with the ranges reported in the published series (34). We have found the two angles analysed to be closely correlated; it therefore can be considered that the more common measurement between the axis of the tibial plateau and the axis of the ankle suffices to establish tibial torsion. In our series we have found no significant differences in tibial torsion according to the preoperative frontal deformity of the extremity—considering 4° as the limiting angulation between normal knees and knees with varus-valgus deformities.

In the postoperative period, the angle between the axis of the ankle and the line joining the centre of the platforms of the prosthetic tibial tray was 15.66°, which represents a

significant difference with respect to preoperative torsion. A decrease in torsion of over 2° on average was obtained. This figure did not change on using CAS, and indirectly confirms that navigation surgery does not improve the rotational position of the prosthetic tibial component. This observation moreover shows that neither standard instrumentation nor CAS precisely reproduce the rotational axis of the leg. We do not know what the clinical repercussions of this change in tibial torsion may be.

Our study has limitations. Firstly, the sample size is limited. The analysed cases are few in number, and subdividing them according to prior frontal deformity reduced the numbers even further—thereby making it difficult to draw statistically valid conclusions. Secondly, we have analysed knees with radiological deformities secondary to advanced osteoarthritis, and this may have modified the preoperative tibial torsion measurements. In this regard, the presence of osteophytes and collapse can give rise to error in measuring the axis of the tibial plateau. We have not investigated whether these differences in tibial torsion persist on using intramedullary guides in standard surgery. Our study is purely radiological, and the findings have not been related to the clinical results. The alterations of the tibial axis may be expected to influence the clinical course and survival of the implant, though this cannot be confirmed at the present time.

After TKR implantation surgery, tibial torsion decreases significantly. The consequences this may have for the clinical outcome of arthroplasty, and whether pain, functional limitation or failure of the procedure may result, is not known.

Acknowledgements

To Jose Manuel Fernandez-Carreira (SESPA, Spain) for statistical calculations.

Funding: This work was supported by a grant from the FIS (Instituto de Salud Carlos III of Spain) with FEDER funding.

Footnote

Conflicts of Interest: The authors have no conflicts of interest to declare.

Ethical Statement: Institutional review board approval was obtained (Regional Ethical Committee of Asturias, Spain, reference PS09/02153C).

References

1. Bourne RB, Chesworth BM, Davis AM, et al. Patient satisfaction after total knee arthroplasty: who is satisfied and who is not? *Clin Orthop Relat Res* 2010;468:57-63.
2. Bédard M, Vince KG, Redfern J, et al. Internal rotation of the tibial component is frequent in stiff total knee arthroplasty. *Clin Orthop Relat Res* 2011;469:2346-55.
3. Valkering KP, Breugem SJ, van den Bekerom MP, et al. Effect of rotational alignment on outcome of total knee arthroplasty. *Acta Orthop* 2015;86:432-9.
4. Maestro A, Harwin SF, Sandoval MG, et al. Influence of intramedullary versus extramedullary alignment guides on final total knee arthroplasty component position: a radiographic analysis. *J Arthroplasty* 1998;13:552-8.
5. Akagi M, Oh M, Nonaka T, et al. An anteroposterior axis of the tibia for total knee arthroplasty. *Clin Orthop Relat Res* 2004;420:213-9.
6. Huddleston JI, Scott RD, Wimberley DW. Determination of neutral tibial rotational alignment in rotating platform TKA. *Clin Orthop Relat Res* 2005;440:101-6.
7. Aglietti P, Sensi L, Cuomo P, et al. Rotational position of femoral and tibial components in TKA using the femoral transepicondylar axis. *Clin Orthop Relat Res* 2008;466:2751-5.
8. Cobb JP, Dixon H, Dandachli W, et al. The anatomical tibial axis: reliable rotational orientation in knee replacement. *J Bone Joint Surg Br* 2008;90:1032-8.
9. Lützner J, Krummenauer F, Günther KP, et al. Rotational alignment of the tibial component in total knee arthroplasty is better at the medial third of tibial tuberosity than at the medial border. *BMC Musculoskelet Disord* 2010;11:57.
10. Dennis DA, Channer M, Susman MH, et al. Intramedullary versus extramedullary tibial alignment systems in total knee arthroplasty. *J Arthroplasty* 1993;8:43-7.
11. Teter KE, Bregman D, Colwell CW Jr. Accuracy of intramedullary versus extramedullary tibial alignment cutting systems in total knee arthroplasty. *Clin Orthop Relat Res* 1995;321:106-10.
12. Reed MR, Bliss W, Sher JL, et al. Extramedullary or intramedullary tibial alignment guides: a randomised, prospective trial of radiological alignment. *J Bone Joint Surg Br* 2002;84:858-60.
13. Eckhoff DG, Johnson KK. Three-dimensional computed tomography reconstruction of tibial torsion. *Clin Orthop Relat Res* 1994;302:42-6.
14. Morawa LG, Manley MT, Edidin AA, et al. Transesophageal echocardiographic monitored events during total knee arthroplasty. *Clin Orthop Relat Res* 1996;331:192-8.
15. Church JS, Scadden JE, Gupta RR, et al. Embolic phenomena during computer-assisted and conventional total knee replacement. *J Bone Joint Surg Br* 2007;89:481-5.
16. Cinotti G, Sessa P, Rocca AD, et al. Effects of tibial torsion on distal alignment of extramedullary instrumentation in total knee arthroplasty. *Acta Orthop* 2013;84:275-9.
17. Ikeuchi M, Yamanaka N, Okanou Y, et al. Determining the rotational alignment of the tibial component at total knee replacement: a comparison of two techniques. *J Bone Joint Surg Br* 2007;89:45-9.
18. Thienpont E, Fennema P, Price A. Can technology improve alignment during knee arthroplasty. *Knee* 2013;20 Suppl 1:S21-8.
19. Hernandez-Vaquero D, Noriega-Fernandez A, Fernandez-Carreira JM, et al. Computer-assisted surgery improves rotational positioning of the femoral component but not the tibial component in total knee arthroplasty. *Knee Surg Sports Traumatol Arthrosc* 2014;22:3127-34.
20. Clarke HD. Tibial component rotation: The inveterate problem. *Knee* 2014;21:879-80.
21. Nicoll D, Rowley DI. Internal rotational error of the tibial component is a major cause of pain after total knee replacement. *J Bone Joint Surg Br* 2010;92:1238-44.
22. Feczko PZ, Pijls BG, van Steijn MJ, et al. Tibial component rotation in total knee arthroplasty. *BMC Musculoskelet Disord* 2016;17:87.
23. Kim YH, Park JW, Kim JS, et al. The relationship between the survival of total knee arthroplasty and postoperative coronal, sagittal and rotational alignment of knee prosthesis. *Int Orthop* 2014;38:379-85.
24. Sahin N, Atıcı T, Öztürk A, et al. Accuracy of anatomical references used for rotational alignment of tibial component in total knee arthroplasty. *Knee Surg Sports Traumatol Arthrosc* 2012;20:565-70.
25. Bonnin MP, Saffarini M, Mercier PE, et al. Is the anterior tibial tuberosity a reliable rotational landmark for the tibial component in total knee arthroplasty? *J Arthroplasty* 2011;26:260-7.e1-2.
26. Tao K, Cai M, Zhu Y, et al. Aligning the tibial component with medial border of the tibial tubercle--is it always right? *Knee* 2014;21:295-8.
27. Chiu KY, Yau WP, Ng TP, et al. The accuracy of extramedullary guides for tibial component placement in total knee arthroplasty. *Int Orthop* 2008;32:467-71.

28. Kuriyama S, Hyakuna K, Inoue S, et al. Tibial rotational alignment was significantly improved by use of a CT-navigated control device in total knee arthroplasty. *J Arthroplasty* 2014;29:2352-6.
29. Meijer MF, Reininga IH, Boerboom AL, et al. Does imageless computer-assisted TKA lead to improved rotational alignment or fewer outliers? A systematic review. *Clin Orthop Relat Res* 2014;472:3124-33.
30. Jazrawi LM, Birdzell L, Kummer FJ, et al. The accuracy of computed tomography for determining femoral and tibial total knee arthroplasty component rotation. *J Arthroplasty* 2000;15:761-6.
31. Turner MS, Smillie IS. The effect of tibial torsion of the pathology of the knee. *J Bone Joint Surg Br* 1981;63-B:396-8.
32. Enomoto H, Nakamura T, Waseda A, et al. A novel and reproducible reference axis for distal tibial axial rotation. *J Arthroplasty* 2013;28:788-91.
33. Mizu-uchi H, Matsuda S, Miura H, et al. The effect of ankle rotation on cutting of the tibia in total knee arthroplasty. *J Bone Joint Surg Am* 2006;88:2632-6.
34. Yagi T, Sasaki T. Tibial torsion in patients with medial-type osteoarthritic knee. *Clin Orthop Relat Res* 1986;213:177-82.

Cite this article as: Hernandez-Vaquero D, Noriega-Fernandez A, Roncero-Gonzalez S, Sierra-Pereira AA, Sandoval-Garcia MA. Total knee replacement modifies the preoperative tibial torsion angle—similar results between computer-assisted and standard technique. *Ann Transl Med* 2018;6(7):113. doi: 10.21037/atm.2018.02.15