



Computed tomography is not necessary to assess rotation of the femoral component in navigation-assisted total knee replacement

Daniel Hernández-Vaquero^{1,2},
Alfonso Noriega-Fernandez²,
Ivan Perez-Coto², Manuel A Sandoval García²,
Andres A Sierra-Pereira²,
Sergio Roncero-Gonzalez² and
Jose Manuel Fernandez-Carreira²

Abstract

Objective: To demonstrate that postoperative computed tomography (CT) is not needed if navigation is used to determine the rotational position of the femoral component during total knee replacement (TKR).

Methods: Preoperative CT, navigational, and postoperative CT data of 70 TKR procedures were analysed. The correlation between the rotational angulation of the femur measured by CT and that measured by perioperative navigation was examined. The correlation between the femoral component rotation determined by navigation and that determined by CT was also assessed.

Results: The mean femoral rotation determined by navigation was $2.64^\circ \pm 4.34^\circ$, while that shown by CT was $6.43^\circ \pm 1.65^\circ$. Postoperative rotation of the femoral component shown by CT was $3.09^\circ \pm 2.71^\circ$, which was closely correlated with the angle obtained through the intraoperative transepicondylar axis by navigation (Pearson's $R = 0.930$).

Conclusions: Navigation can be used to collect the preoperative, intraoperative, and postoperative data and final position of the TKR. The rotation of the femoral component can be determined using navigation without the need for CT.

¹School of Medicine, University of Oviedo, Spain

²Hospital San Agustín, Aviles, Spain

Corresponding author:

Daniel Hernández-Vaquero, Heros, 4. 33400-Aviles,
Asturias, Spain.

Email: danielhvaquero@gmail.com



Keywords

computed tomography, computer-assisted surgery, femoral rotation, navigation, total knee replacement

Date received: 27 May 2016; accepted: 29 July 2016

Introduction

Correct placement and alignment of the components during total knee replacement (TKR) is a priority. Although mechanical instrumentation is crucial to ensure optimal positioning in the coronal plane, the same cannot be said for positioning in the rotational plane. However, mechanical instrumentation does not allow for an individualized technique; only an approximation to the optimal position can be achieved.

Computer-assisted surgery (CAS) improves placement of the tibial and femoral components and affords better reproduction of the mechanical axis of the limb. Identification of the centre of rotation of the femoral head and palpation of the anatomical surfaces of the knee and ankle allow for determination of the true preoperative mechanical axis and guide the surgical procedures involving the bone and soft tissue while securing the optimum axis (from -3° to $+3^\circ$).

Imageless navigation systems use different methods, almost always in combination, to establish the preoperative femoral rotation. These methods include palpation of the epicondyles to trace the transepicondylar axis, palpation of Whiteside's anteroposterior line, or mapping of the posterior surface of the femoral condyles. Based on an algorithm, the navigation software indicates the initial femoral rotation and informs the surgeon of optimum placement of the implant component, thereby facilitating individualized positioning.

Reports in the literature have raised controversy regarding the accuracy and therefore reliability of palpation of the bony prominences when using perioperative CAS measurements to orient the femoral

component.^{1,2} Some systems³ use a combination of various measurements, such as palpation of the epicondyles and Whiteside's anteroposterior line.

Navigation systems collect and archive the data obtained during surgery and make it possible to determine the final position of the prosthetic components in both the anteroposterior and rotational axes. Determination of the final position eliminates the need to perform other examinations, such as computed tomography (CT), in the event of complications arising from malpositioning of the arthroplasty. Demonstration that the rotation of the femoral component determined by navigation coincides with that determined by postoperative CT would be clinically useful because the postoperative CT examination could then be avoided.

The present study had the following objectives:

- (1) To determine whether measurement of femoral rotation obtained by preoperative CT coincides with that obtained by computer-assisted navigation.
- (2) To determine whether isolated measurement of the transepicondylar axis using the navigation system is closely correlated with the preoperative femoral rotation axis and therefore whether this isolated measurement is sufficient.
- (3) To determine the relationship between the rotation determined by palpation of the epicondylar prominences using CAS and the position of the femoral component after implantation.
- (4) In summary, to demonstrate that CT is not needed to assess rotation of the TKR femoral component if navigational CAS is used because the definitive

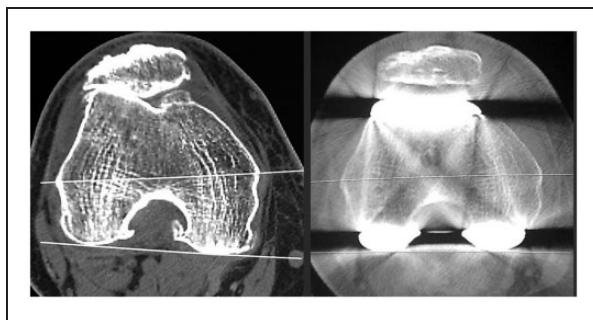


Figure 1. Preoperative and postoperative CT femoral rotation measurements.

position of this component is reflected in the final report of the navigation.

Patients and methods

All patients provided written informed consent. This work forms part of a project that was approved by the Regional Ethics Committee of Asturias (Spain) (Ref. PS09/02153).

All patients evaluated in this study had been diagnosed with osteoarthritis of the knee and had undergone 3 months of medical and physical therapeutic treatment with unsuccessful results. Thus, navigation-assisted TKR was performed. Radiographic evaluation of the hip, knee, and ankle in the frontal and lateral positions during the preoperative assessment of all patients. The mechanical axis of the limb and angulation of the femoral and tibial components were measured on X-ray films using Impax 6.3.1.2813 and Orthopaedic Tools version 2.06 software (Agfa HealthCare nV, Mortsel, Belgium).

Preoperative and postoperative CT examinations of the femoral condylar region were performed in all patients. The CT scanner used was a SOMATOM Volume Access system, version A40A (Siemens AG, Munich, Germany). At least three sections of the femur were made until the best view of both epicondyles and the semi-spherical-

shaped portion of the epicondylar tunnel was obtained. The distal metaphyseal axial angulation of the femur was determined, using the transepicondylar line and the line between the posterior condylar ridges as a reference (Figure 1). The clinical epicondyle, defined as the greatest protrusion of the lateral and medial epicondyles, was used to obtain this measurement. Similar references were used in the postoperative CT scan. The angulation considered to be valid was the mean of those separately reported by two radiologists.

An image-free navigation system (Stryker Navigation System, 4.0; Stryker Leibinger, Freiburg, Germany) was used for computer-assisted implantation. The system used infrared cameras and light-emitting diodes. Surgery was performed under a tourniquet. The patella was everted in all patients. The landmarks comprised the centre of the femoral head, the distal femur, the proximal tibia, the ankle, Whiteside's axis, the epicondylar axis (lateral and medial epicondyles) (Figure 2), the anterior surface of the distal femoral cortex, the condylar surfaces of the femur and tibia, and the tibial anteroposterior axis. The reliability of palpation of the epicondyles and of Whiteside's axis was agreed upon by the two principal surgeons, both of whom had extensive experience with this type of surgery. The femoral rotation axis on the navigation system was defined as the average rotational

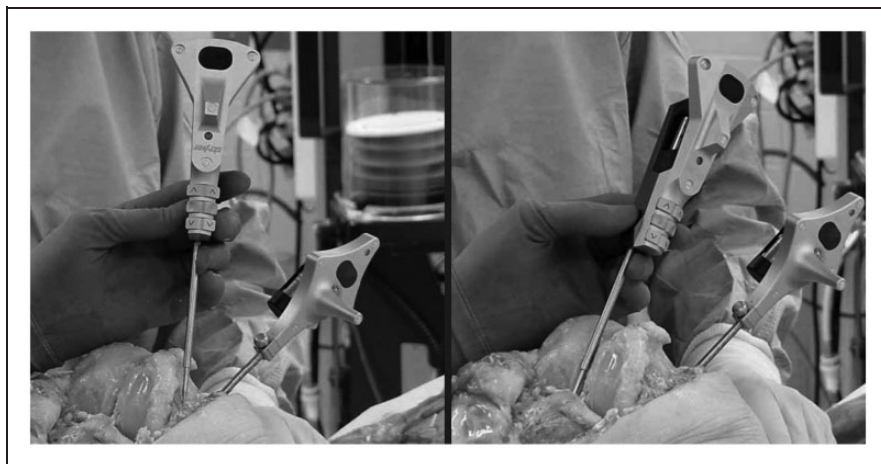

Figure 2. Intraoperative acquisition of epicondylar and Whiteside's axis references.

axis of the transepicondylar axis and the axis perpendicular to Whiteside's axis (Figure 3). CAS was used to fix the orientation of the cutting guide on the distal femur at 3° of external rotation. The implant model used in all cases was the Stryker Triathlon knee (Stryker, Kalamazoo, MI, USA).

The statistical tests used were Pearson's correlation (Pearson's R) and reliability analysis with intraclass correlation (Cronbach's alpha).

Results

In total, 70 patients who underwent navigation-assisted TKR were prospectively studied. The mean age of the patients was 62 ± 7.12 years, and the mean body mass index was $30 \pm 5.45 \text{ kg/m}^2$ (range 19.88–44.00). Women represented 78% of the total sample. Preoperative femoral rotation measurements were obtained in 64 patients; defective identification of the anatomical references in the CT study precluded measurement in the remaining 6 patients. The mean frontal preoperative mechanical femorotibial angle was $1.85^\circ \pm 9.12^\circ$ (range -20° to -20°). The initial femoral rotation of the series measured by CT was

$6.43^\circ \pm 1.65^\circ$ (range 4° – 10°). Preoperative femoral rotation was assessed via CT considering the presence of varus-valgus deformities. Without deformities of $\leq 4^\circ$, the mean rotation was 6.62° , whereas in the presence of deformities of $>4^\circ$, the mean rotation was 6.56° . The difference between these values was not statistically significant. The mean rotation as determined by perioperative navigation was $2.82^\circ \pm 4.17^\circ$ (range -7° to 12°). No correlation was found between the rotation measured by CT and that measured by the navigation system before implantation (Cronbach's alpha = -0.275).

The mean femoral rotation determined by the navigation system through the transepicondylar line was $2.64^\circ \pm 4.34^\circ$ (range -8° to 12°). Comparison of the rotation measured from the epicondyles versus the definitive rotation, which also considers Whiteside's line and was calculated as $2.82^\circ \pm 4.17^\circ$ (range -7° to 12°), revealed a strong correlation ($P < 0.001$, Pearson's R = 0.848) (95% confidence interval 0.7509, 0.9081) (Figure 4).

The postoperative rotation of the femoral component was $3.09^\circ \pm 2.71^\circ$ (range -2° to 9°), which was closely correlated with the

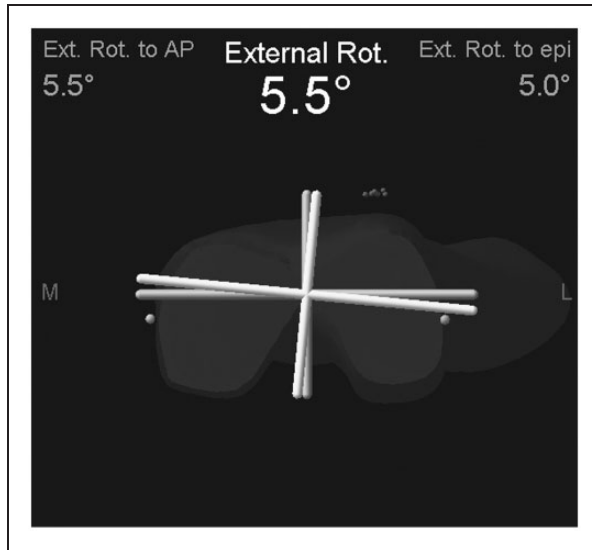


Figure 3. Preoperative navigator screen. Femoral rotation from the anteroposterior axis and transepicondylar axis.

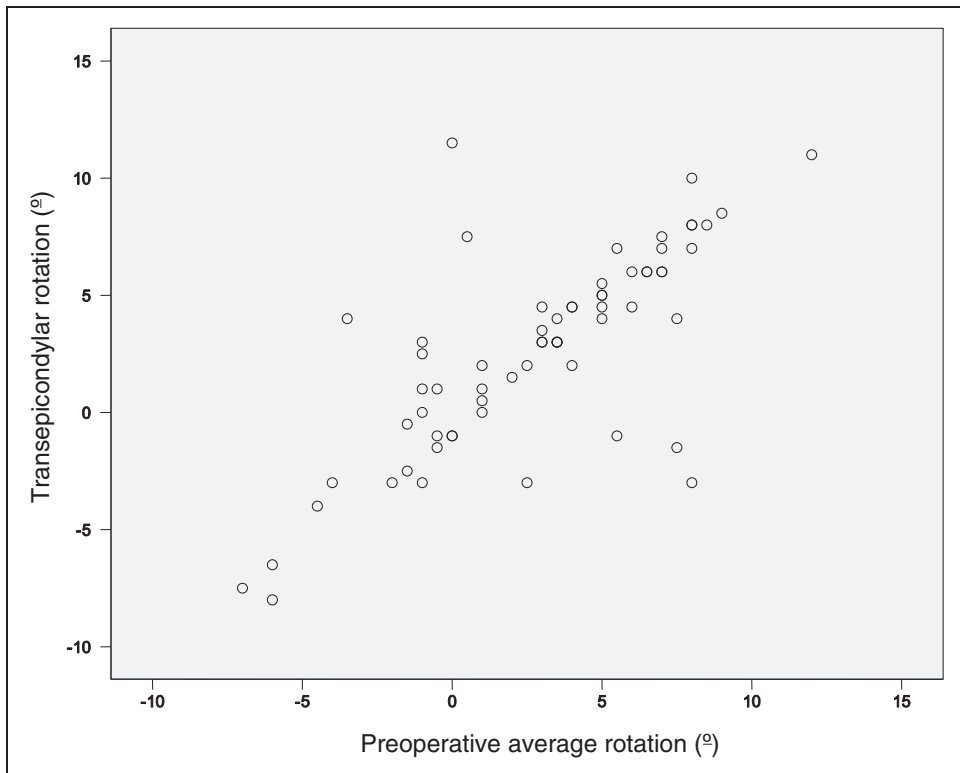


Figure 4. Scatter plot showing the correlation between epicondylar rotation and mean preoperative rotation.

angle obtained through the transepicondylar axis (2.64°) using the navigation system ($P < 0.001$, Pearson's $R = 0.930$).

Discussion

The aim of the present study was to determine whether a close correlation is present between the distal femur rotation obtained by navigation and that obtained by postoperative CT. The most important finding of the present study is that CT is not needed if CAS is used for arthroplasty and the position of the prosthetic components is archived in the navigation system.

To date, navigation has mainly been used to improve implant alignment and evaluate the soft tissues during TKR. However, CAS might also be useful in avoiding the need for preoperative CT, postoperative alignment control, and evaluation of patellar complications associated with poor alignment of the extensor apparatus. Obviating the need for CT would reduce costs and radiation exposure.

The advantages of CAS in the mid- and short-term course following TKR are controversial. CAS has been proposed as a technique with which to improve implant alignment during TKR. However, while improved implant alignment is considered to result in better clinical outcomes, the existing data on this topic are inconclusive.⁴ Some authors^{5,6} recently reported that CAS reduces revision surgery due to loosening and lysis, while other investigators found no differences in the short- and mid-term outcomes.^{7,8} Despite the contradictory data found in the literature,⁹ CAS appears to avoid outliers and large malalignments and, in a large percentage of cases, secure an optimum mechanical axis in the frontal plane.

Rotational malalignment is a major cause of knee pain and failure after total knee arthroplasty.^{10,11} The usefulness of CAS in correctly positioning TKR in the rotational

plane has been questioned in the literature, even more so than its usefulness in the frontal plane. Some authors have described better rotational positioning of the femoral component with CAS,¹²⁻¹⁴ particularly in the context of large valgus deformities,¹⁵ although other authors have reported no such advantage.¹⁶

There is agreement in the literature on the usefulness of CT for measuring femoral rotation. The rotational axis in the distal femur is determined from the angle between the line tangential to the posterior condyles and the transepicondylar line or epicondylar axis. The transepicondylar axis is regarded as a consistent reference for identifying the coronal plane.^{17,18} The so-called clinical epicondyles were used as references in the present study. These are defined as the greatest protrusion of the lateral and medial epicondyles and conform to the anatomical transepicondylar axis. Use of the clinical epicondyles allows for better comparison of the initial rotation determined by navigation and palpation of the bone prominences versus the data obtained by CT.

Differences between the preoperative rotation determined by CT and that obtained by navigation have been previously described.¹⁹ The differences in these data may be due to the fact that CT exclusively measures rotation of the distal femur from the femoral condyles, while the rotation reflected by the navigation system is the true rotation obtained from the mechanical axis of the limb, generated from the centre of the femoral head. According to other authors,²⁰ such discrepancies can be explained by the presence of cartilage, which is not seen on the CT scan, or by the different reference planes used in the two techniques. In the present study, the mean rotation obtained by CT was 6.43° , while that obtained by the navigation system was 2.82° . The correlation between the two techniques was low. This apparently contradictory finding is simply a result of having

measured two different axes and reflects the difference between rotation measured in the femur (anatomical axis) and true rotation measured through the mechanical axis of the limb. Utilization of the navigation system makes preoperative measurement of rotation with CT unnecessary because the final rotation must seek to ensure the best positioning of the implant in the mechanical axis of the entire extremity, not only using the femoral supracondylar zone as a reference. CAS therefore reflects the true femoral rotation. Despite the abundant amount of literature on CAS, no reports have justified this discrepancy in the rotation measurement between CAS and CT.

The gap balancing technique, posterior condylar line, anteroposterior axis (so-called Whiteside's line), and epicondylar axis have been used to establish femoral rotation,^{21,22} but identification of these axes using bony landmarks on the distal part of the femur is highly variable. Using the present navigation system, the preoperative femoral rotation is determined through an algorithm that takes the transepicondylar axis and an imaginary Whiteside's line as measures. Collection of this information may imply errors during the registration process.²³ Whiteside's axis is generally assumed to be perpendicular to the transepicondylar axis and therefore serves as a reliable axis of reference. However, criticism of this landmark has arisen because of identification difficulties in patients with trochlear dysplasia or destructive osteoarthritis.⁹ Some researchers have recommended the use of an average algorithm between the determined angle of the registered Whiteside's axis and the transepicondylar axis, and Stockl et al.¹³ showed that image-free navigation using this algorithm improved the femoral rotational alignment. Siston et al.²⁴ in turn analysed the accuracy and precision of different references: Whiteside's line, the posterior condyles, the digitized epicondyles, and kinematic patella tracking. Use

of the posterior condyles was the least precise among the four reference techniques. The combination of the digitized epicondyles and Whiteside's line, which is a technique used in the present navigation system, showed less error than the other techniques.

In the present study, the mean femoral rotation recorded with the navigation system through the transepicondylar line was $2.64^\circ \pm 4.34^\circ$ (range -8° to 12°), and the definitive rotation was $2.82^\circ \pm 4.17^\circ$ (range -7° to 12°). A strong correlation was found upon comparison of the rotation as measured from the epicondyles and the definitive rotation ($P < 0.001$, Pearson's $R = 0.848$) (95% confidence interval 0.7509, 0.9081). This strong correlation may imply that determination of the femoral anteroposterior axis is not necessary and that the transepicondylar axis is sufficient. This would shorten the time spent obtaining references for navigation.

The current study revealed a strong correlation between the transepicondylar axis determined by the intraoperative CAS measurements used to orient the femoral component (mean 2.64°) and the femoral component axis determined by the postoperative CT study (mean 3.09°). This observation implies that the anatomical references used in navigation to determine the transepicondylar axis in the present study are reliable. However, it may imply that postoperative CT is not needed to assess rotation of the femoral component. This is very important because identification of the rotational position of the femoral component using the navigation system would obviate the need for CT examination of anterior pain or patellar complications, including subluxations or luxations, in the evolution of TKR. Because the navigation data are collected and stored, highly valuable information is available that could replace that provided by CT.

The present study has limitations. Preoperative identification of the

epicondyles with CT was not possible in some cases, and these cases were thus rejected from the analysis. A better radiological technique and an increase in the number of CT sections might have allowed for determination of the transepicondylar axis in all patients. However, this would have resulted in increased radiation exposure. Therefore, these patients were excluded. Another limitation is the lack of hip CT to determine antetorsion of the femoral neck and head and thus establish the mechanical axis of the limb. This limitation prevented correction of the absence of the correlation of the pre-operative rotation obtained between CT and that obtained by the navigation system.

In recent years, the literature on the usefulness of CAS in TKR has yielded often contradictory results. Nevertheless, CAS has been shown to improve alignment of the extremity after TKR. Whether this implies better outcomes and longer implant survival, however, remains to be determined. The strong correlation between the rotational axis of the implant determined by intraoperative CAS and that determined by postoperative CT in the present study is important because it shows that CT is not needed for radiographic control purposes or the study of complications of the extensor apparatus. Overall, the present study indicates that the data collected and stored by CAS (particularly the initial and definitive rotation of the femoral component in TKR) can obviate the need for radiological techniques such as CT, which are associated with high costs, resource utilization, and radiation exposure.

Declaration of conflicting interest

The authors declare that there is no conflict of interest.

Funding

This study was supported financially by the Health Research Institute (Carlos III Health

Institute) of the Spanish National Healthcare System (FIS-FEDER).

References

1. Jenny JY and Boeri C. Low reproducibility of the intra-operative measurement of the transepicondylar axis during total knee replacement. *Acta Orthop Scand* 2004; 75: 74–77.
2. Yau WP, Leung A, Liu KG, et al. Interobserver and intra-observer errors in obtaining visually selected anatomical landmarks during registration process in non-image-based navigation-assisted in total knee arthroplasty. *J Arthroplasty* 2007; 22: 1150–1161.
3. Restrepo C, Hozack WJ, Orozco F, et al. Accuracy of femoral rotational alignment in total knee arthroplasty using computer assisted navigation. *Comput Aided Surg* 2008; 13: 167–172.
4. Donaldson J, Joyner J and Tudor F. Current controversies of alignment in total knee replacements. *Open Orthop J* 2015; 9(Suppl 2: M6): 489–494.
5. de Steiger RN, Liu Y-L and Graves SE. Computer navigation for total knee arthroplasty reduces revision rate for patients less than sixty-five years of age. *J Bone Joint Surg Am* 2015; 97: 635–642.
6. Singiseti K, Muthumayandi K, Abual-Rub Z, et al. Navigation-assisted versus conventional total knee replacement: no difference in patient-reported outcome measures (PROMs) at 1 and 2 years. *Arch Orthop Trauma Surg* 2015; 135: 1595–1601.
7. Hernández-Vaquero D, Suarez-Vazquez A and Iglesias-Fernandez S. Can computer assistance improve the clinical and functional scores in total knee arthroplasty? *Clin Orthop Relat Res* 2011; 469: 3436–3442.
8. Cheng T, Zhao S, Peng X, et al. Does computer-assisted surgery improve post-operative leg alignment and implant positioning following total knee arthroplasty? A meta-analysis of randomized controlled trials? *Knee Surg Sports Traumatol Arthrosc* 2012; 20: 1307–1322.
9. Barrack RL, Schrader T, Bertot AJ, et al. Component rotation and anterior knee pain after total knee arthroplasty. *Clin Orthop Relat Res* 2001; 92: 46–55.

10. Valkering KP, Breugem SJ, van den Bekerom MP, et al. Effect of rotational alignment on outcome of total knee arthroplasty. *Acta Orthopaedica* 2015; 86: 432–439.
11. Stöckl B, Nogler M, Rosiek R, et al. Navigation improves accuracy of rotational alignment in total knee arthroplasty. *Clin Orthop Relat Res* 2004; 426: 180–186.
12. Hernandez-Vaquero D, Noriega-Fernandez A, Fernandez-Carreira JM, et al. Computer-assisted surgery improves rotational positioning of the femoral component but not the tibial component in total knee arthroplasty. *Knee Surg Sports Traumatol Arthrosc* 2014; 22: 3127–3134.
13. Zambianchi F, Luyckx T, Victor J, et al. How to improve femoral component rotational alignment in computer-assisted TKA. *Knee Surg Sports Traumatol Arthrosc* 2014; 22: 1805–1811.
14. Lin SJ, Lee CY, Huang KC, et al. Improved femoral component rotation in advanced genu valgum deformity using computer-assisted measured resection total knee arthroplasty. *J Orthop Surg Res* 2015; 10: 135.
15. Meijer MF, Reininga HF, Boerboom AL, et al. Does imageless computer-assisted TKA lead to improved rotational alignment or fewer outliers? A systematic review. *Clin Orthop Relat Res* 2014; 472: 3124–3133.
16. Yoshioka Y, Siu D and Cooke TD. The anatomy and functional axes of the femur. *J Bone Joint Surg Am* 1987; 69: 873–880.
17. Kreuzer SW, Pourmoghaddam A, Leffers K, et al. Computed tomography analysis of postsurgery femoral component rotation based on a force sensing device method versus hypothetical rotational alignment based on anatomical landmark method: a pilot study. *Adv Orthopedics* 2016; 2016: 4961846. doi: 10.1155/2016/4961846.
18. Kobayashi H, Akamatsu Y, Kumaga K, et al. The surgical epicondylar axis is a consistent reference of the distal femur in the coronal and axial planes. *Knee Surg Sports Traumatol Arthrosc* 2014; 22: 2947–2953.
19. Van der Linden-van der Zwaag HM, Valstar ER, van der Molen AJ, et al. Transepicondylar axis accuracy in computer assisted knee surgery: a comparison of the CT-based measured axis versus the CAS-determined axis. *Comput Aided Surg* 2008; 13: 200–206.
20. de Ladoucette A. CT measurements prior to computer-assisted total knee arthroplasty do not improve rotational placement of the femoral component. *Knee Surg Sports Traumatol Arthrosc* 2012; 20: 2471–2475.
21. Uemura K, Takao M, Sakai T, et al. The validity of using the posterior condylar line as a rotational reference for the femur. *J Arthroplasty* 2016; 31: 302–306.
22. Vanin N, Panzica M, Dikos G, et al. Rotational alignment in total knee arthroplasty: intraoperative inter- and intraobserver reliability of Whiteside's line. *Arch Orthop Trauma Surg* 2011; 131: 1477–1480.
23. Jerosch J, Peuker E, Philipps B, et al. Interindividual reproducibility in perioperative rotational alignment of femoral components in knee prosthetic surgery using the transepicondylar axis. *Knee Surg Sports Traumatol Arthrosc* 2002; 10: 194–197.
24. Siston RA, Cromie MJ, Gold GE, et al. Averaging different alignment axes improves femoral rotational alignment in computer-navigated total knee arthroplasty. *J Bone Joint Surg Am* 2008; 90: 2098–2104.